



Case Study

ROLE OF JALAUKA AVCHARANA AND AYURVEDIC MANAGEMENT IN DADRU KUSHTHA

Ajay Pratap Singh^{1*}, Nandini Shah²

¹MS Scholar, Dept. of Shalya Tantra, UAU Gurukul Campus Haridwar, Uttarakhand, India.

² Medical Officer (Ayurved), Govt. Ayurved Hospital Mundoli deval block, Chamoli, Uttarakhand, India.

Article info

Article History:

Received: 28-12-2024

Accepted: 24-01-2025

Published: 07-02-2025

KEYWORDS:

Dadru,
Jalaukavacharana,
Kshudra kushtha,
Tinea corporis.

ABSTRACT

A massive increase in incidence of skin problems can be seen in tropical and developing countries like India. *Dadru* (*Tinea corporis*) is one of the most encountered skin diseases occurring due to unhygienic conditions, poverty, poor sanitation, sun exposure etc. *Dadru* is described under *Kshudra kushtha* in *Charaka Samhita*, which if left untreated it seeps into deeper tissues and becomes difficult to cure. For present study, a male patient of 15 yrs age visited department of Shalya tantra at Uttarakhand Ayurved University Gurukul Campus Haridwar with complaint of widespread patches and severe itching over back side of neck from 6 months. He also had on and off constipation from 15 days, disturbed sleep for 2 months and loss of appetite. There was no significant past history of any other chronic disorder. The patient was diagnosed with *Dadru kushtha* (*Tinea corporis*) on the basis of clinical symptoms and investigations. Patient was treated with Ayurvedic para surgical process (*Jalaukavachran*) along with oral Ayurvedic medicines like *Arogya vardhni vati*, *Nimbadi churna*, *Gandhak bhasma*, *Trikatu churna*, *Khadirarishta*, *Triphala churna* for 45 days. A significant response was observed over clinical symptoms, healing and recovery of *Dadru*.

INTRODUCTION

Human skin acts as a barrier to many infections reflecting the health of an individual. There has been a considerable increase in incidence of skin problems. According to contemporary science, the symptoms of tinea include a ring-shaped elevated circular that is itchy, red, and scaly^[1]. *Dadru* is a prevalent *Kushtha roga*, which is classified under *Kshudra kushtha* by *Acharya Charak* and under *Mahakushtha* by *Acharya Sushrut* and *Vagbhatta*. *Seta Dardu* and *Aseta* are described in *Sushruta Samhita*^[2]. *Kandu*, *Raga*, *Unnata pidaka* and *Parimandal* are the *Lakshanas* of *Dadru* that are described in the classics. It typically affects the back side of neck region. Antibiotics, anti-fungals, anti-histamines, topical medications and steroids are used as treatment in modern science whereas Ayurvedic treatment includes *Shaman aushadhi*, *Asava*, *Arista*, *Lepa*, *Parisheka* and *Shodhana* procedures such as *Vamana*, *Virechana*, and *Raktamokshana*.^[3]

One kind of *Raktamokshana* by *Jalauka* as a living being, is *Jalauka avacharana*. Hirudine, which has antioxidant and anti-inflammatory properties is present in it which improves blood flow and reduces itching. It is the simplest and safest way to perform *Raktamokshana*.

Case Report

A 15 year old male patient visited department of Shalya tantra at Uttarakhand Ayurved University Gurukul Campus, Haridwar, with complaint of widespread patches and severe itching over back side of neck from 6 months. He also had on and off constipation from 15 days, disturbed sleep for 2 months and loss of appetite. Patient was normal before 6 months.

There was no significant past history of any other chronic disorder. The patient was diagnosed with *Dadru kushtha* (*Tinea corporis*) on the basis of clinical symptoms and investigations. Patient took various local and oral allopathic medications but was not relieved. He was treated with Ayurvedic para surgical process (*Jalaukavachran*) along with oral Ayurvedic medicines like *Arogya vardhni vati*, *Nimbadi churna*, *Gandhak bhasma*, *Trikatu churna*, *Khadirarishta*, *Triphala churna* for 45 days. A

Access this article online	
Quick Response Code	
	https://doi.org/10.47070/ijapr.v13i1.3476
Published by Mahadev Publications (Regd.) publication licensed under a Creative Commons Attribution-NonCommercial-ShareAlike 4.0 International (CC BY-NC-SA 4.0)	

significant response was observed over clinical symptoms, healing and recovery of *Dadru*.

Demographic profile

Name- xxx

Age- 15 years

Sex- Male

Address- Haridwar

Occupation- Student

Marital status- Unmarried

Physical Examination

Pulse: 80/ min

Temp: 98.7° F

B. P. 120/80

R. R. 20/ min

Weight: 51kg

Height: 164cm

Past History

No significant past history

No history of DM /HTN or any other chronic or systemic illness

Personal History

Diet- Mixed

Appetite- Reduced

Bowel- Disturbed (on and off constipation)

Sleep- Disturbed

On Examination

Uneven patches over the neck region

Elevations present (*Kapha janya uttanata*)

Redness (*Ragata*)

Inflammation present

Pidaka

Investigations

Hb %, TLC, DLC, ESR

Samprapti ghatak

Dosha: Vata, Pitta, Kapha dushti shonita kushtha rogas

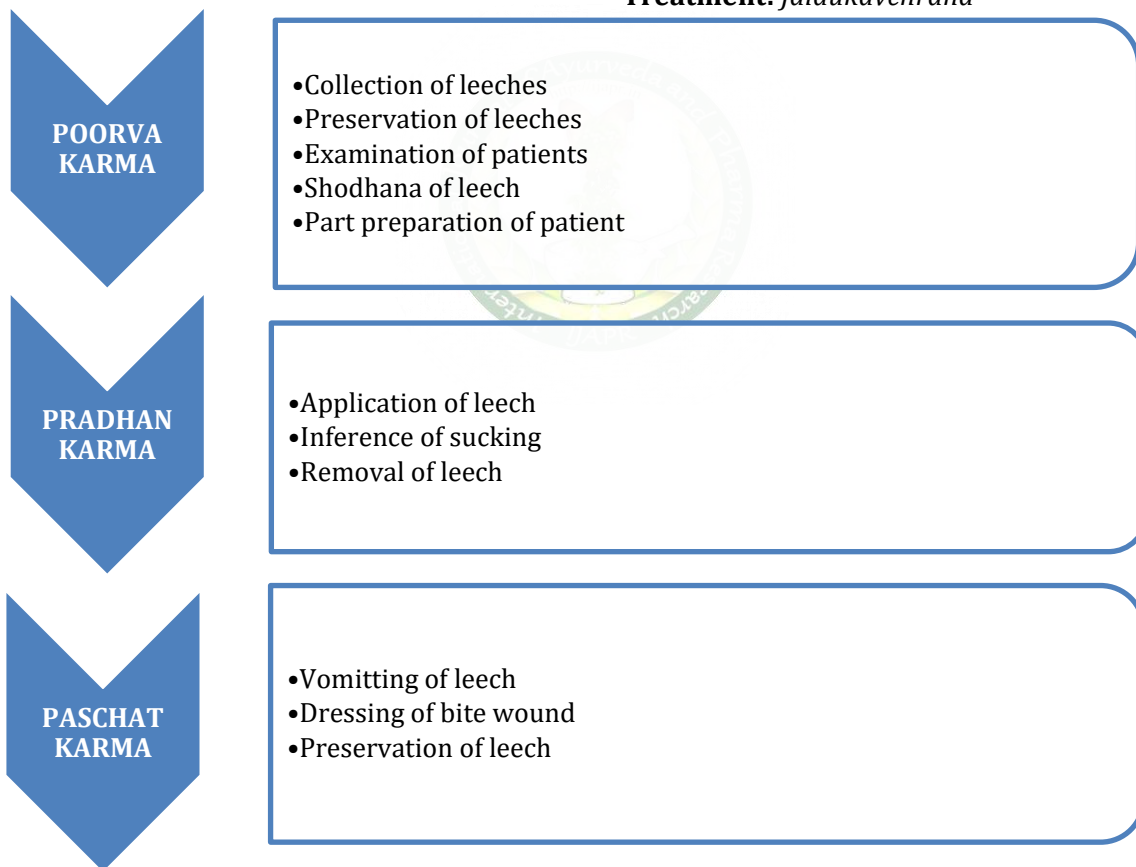
Dushya: Twak, Mamsa, Sira

Mala: Baddha

Srotas: Rasa, Rakta, Mamsa, Purisha and Manovaha

Diagnosis: *Dadru kushtha* (Tinea corporis)

Treatment: *Jalaukavchrana*



1. *Sarwanga snehan* with *Pinda taila*
2. *Prakshalana* with *Panchvalkal kwath* and *Triphala kwath*
3. Six sittings of *Jalukavacharana* were done keeping gap of 5-7 days
4. In each sitting 4-5 leeches were applied

Oral medications

Name	Dose	Frequency
Tab. <i>Arogyavardhani vati</i>	125 mg	Twice daily
<i>Nimbadi churna</i>	3 gm	Twice daily
<i>Gandhak Bhasma</i>	125 mg	
<i>Trikatu churna</i>	1gm	
<i>Khadir arishta</i>	20 ml	Twice daily
<i>Triphala churna</i>	3 gm	Once at night

Anupana: Jal

Kaala: Adhobhakta (after meal)

Route of administration: oral

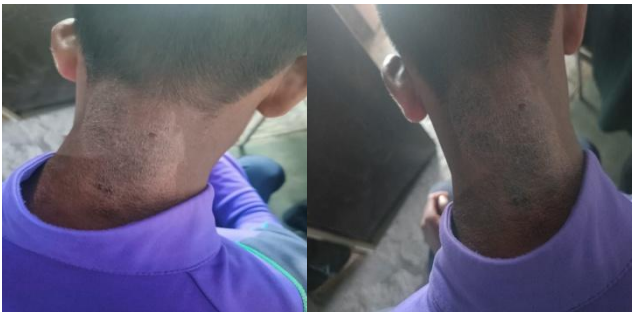Duration: 45 days

Pathya: Moong, rice, Ghee easily digestible foods

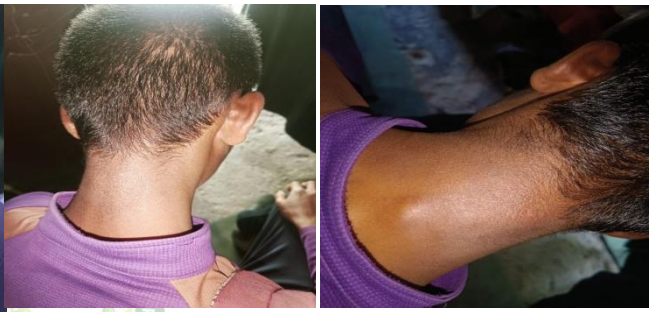Apathya: jaggery, curd, fish, sour fruits, heavy foods

OBSERVATION AND RESULTS

Before Treatment



After Treatment



Mode of Action

Jalaukavacharana

In *Jalaukavacharana* leeches are used, which release compounds like hirudite that have anti-inflammatory and antioxidant properties to perform a specialized type of *Raktamokshana* (bloodletting). By eliminating pollutants from the blood, this process improves local blood circulation, reduces inflammation and detoxifies the blood. In contrast to traditional therapies, leech therapy provides quick relief with little to no discomfort. It pacifies *Pitta Kapha Dosh*a which are the main *Dosha* involved in *Dadru*.

In this case study, *Jalaukavacharana* was effectively used in conjunction with oral Ayurvedic drugs to treat *Dadru Kushtha* symptoms, resulting in quicker symptom relief and successful patient recovery.

Role of Ayurvedic medications

The therapeutic regimen was supported by the administration of *Shamana oushadhis* (herbal medicines) in addition to *Jalaukavacharana*. *Arogyavardhini Vati*, *Nimbadi churna*, *Gandhak bhasma*, *Trikatu churna*, *Khadirarishta* and *Triphala churna* were among them. They aid in reducing inflammation and enhancing general wellness. *Arogyavardhini vati* pacifies *Pitta dosha*, *Nimbadi churna* helps in purifying blood as well as reduces *Kapha dosha*. *Gandhak*

reduces inflammation whereas *Trikatu churna* helps in balancing aggravated *Kapha dosha* and increases *Agni* (digestive enzymes). On the other hand, *Khadirarishta* has anti-inflammatory, anti-oxidant and detoxification properties. *Triphala churna* balances all three *Doshas*, it has detoxifying properties and improves immunity. All the medications pacify *Kapha* and *Pitta* which are the main *Doshas* involved in *Dadru kushtha*.

The treatment also included a diet that steers clear of irritants like junk and greasy foods and instead emphasizes healthy, nourishing foods. Frequent check-ups revealed a significant improvement in the patient's general health and symptoms including itching and rash redness, demonstrating the effectiveness of Ayurvedic treatment for skin conditions.

CONCLUSION

The results of this case study demonstrate that *Jaloukavacharana* is a low-cost yet efficient method of treating *Dadru Kushtha* and related skin disorders when combined with supporting Ayurvedic drugs and proper diet. The positive results that patient have reported confirm that this holistic approach is preferable to contemporary medicine which is more costly and bears side effects. Thus, incorporating old Ayurvedic methods in skin diseases can yield better

outcomes for patients and possibly improve their quality of life at a reasonable cost.

REFERENCES

1. Acharya Siddhinandan Mishra, Vaidya Harishchandra Simha Kushavaha Charaka Samhita Vol 2 Choukambha Orientation Varanasi. Kushta Chikitsa 7th Chapter. 91/92 Sloka
2. Jonathan Barker Rooks Textbook of Dermatology 9th Edition systemic disease and the skin part 13 p.15
3. Kaviraj Dr Ambikadatta Shashtri Shushruta Samhita Prastavita Dr Pranjivan Manikchand Meheta Chowkambha Sanskrit Sanstahna, Varanasi. Pp.57

Cite this article as:

Ajay Pratap Singh, Nandini Shah. Role of Jalauka Avcharana and Ayurvedic Management in Dadru Kushtha. International Journal of Ayurveda and Pharma Research. 2025;13(1):178-181.

<https://doi.org/10.47070/ijapr.v13i1.3476>

Source of support: Nil, Conflict of interest: None Declared

*Address for correspondence

Dr. Ajay Pratap Singh

MS Scholar,
Dept. of Shalya Tantra,
UAU Gurukul Campus,
Haridwar, Uttarakhand, India.
Email: drajay710@gmail.com

Disclaimer: IJAPR is solely owned by Mahadev Publications - dedicated to publish quality research, while every effort has been taken to verify the accuracy of the content published in our Journal. IJAPR cannot accept any responsibility or liability for the articles content which are published. The views expressed in articles by our contributing authors are not necessarily those of IJAPR editor or editorial board members.

