



Review Article

CONCEPT OF PHANA MARMA IN AYURVEDA & ITS RELATION WITH OLFACTION

Sukhada Kulkarni

Assistant Professor, PZET's College of Ayurveda & Research Center, Akurdi, Pune.

Article info

Article History:

Received: 01-09-2023

Accepted: 22-09-2023

Published: 12-10-2023

KEYWORDS:

Phana Marma,
Gandha-adnyana, Sira,
Olfactory Epithelium,
Olfactory Bulb,
Anosmia, Olfactory
Dysfunction.

ABSTRACT

Marma concept is peculiarity of Ayurveda. These are described as vital points of body featuring articulation of *Mansa-Sira-Snayu-Asthi-Sandhi* and are associated with severe disability when traumatised. *Phana Marma* is one of the *Urdhwa Jatrugata Marma*. According to description from available literature, position of *Phana Marma* is confined to olfactory epithelium along with olfactory fascicle leading to olfactory bulb present over upper 1/3rd of nasal cavity. Lesion of this region leads to olfactory dysfunction, which is very difficult to treat. Any lesion of epithelium of nasal cavity including respiratory epithelium over lower 2/3rd even leads to olfactory dysfunction. So one should consider this concept of *Phana Marma* during treatment of any nasal lesion.

INTRODUCTION

Ayurveda, an ancient Indian science associated with life, focuses mainly on maintaining healthy status of an individual and attending normalcy in case of impaired health.^[1] *Marma Paripalan* and *Marma-badha Varjana* that is avoiding trauma or diseases in *Marma Pradesh* is one of the ways to maintain such a normalcy.^[2] Hence it is essential for any *Vaidya*, to have a brief knowledge about concept of *Marmas* and *Marmaghata*. *Marmas* are the vital points presenting articulation of *Mansa* (muscular part), *Sira* (vasculature), *Snayu* (tendons), *Asthi* (bone) and *Sandhi* (joints)^[3] which are considered as building blocks of body. These *Marmas* are also considered as *Adhishtana* that is site of *Sharir Dosha* (bodily humors) *Soma* (*Kapha*), *Marut* (*Vata*) and *Tej* (*Pitta*) along with *Manasa Doshas* (psychological humors) *Satva*, *Raja* and *Tama* and hence *Prana* that is vitality.^[4] So any trauma to these *Marmas* ultimately leads to loss of life.

Actually in day-to-day practice *Marmaghata* that is trauma to *Marma* doesn't meant by certain death in each and every case.

The effect may vary ranging from severe pain, lifelong inability to death. And according to these effects, these 107 *Marmas*^[5] are classified into 5 groups. [Figure 1].

Whatever classifications are mentioned as per *Ayurvedic Samhitas*, but trauma to any of these *Marmas* leads to vitiation of *Sthanastha* that is locally situated *Vata Dosha*. This vitiated *Vata* travels all over body leading to severe pain and this pain ultimately leads to *Sandhya Nasha* that is loss of consciousness followed by that of life.^[8] This *Prasara* of *Vata* from traumatised *Marma* is possible only due to presence of *Chaturvidha Sira* which are present all over the body in form of network and are associated with *Upasnehana* that is growth and differentiation of body along with *Sharir Anugriha* that is maintenance^[9] and hence any trauma to these *Marmas* or any disease related to them are considered as grave and more difficult to treat.^[10] Even the partial or gentle trauma may lead to severe disability even after its treatment by expertise.^[11]

Among all 107 *Marmas*, *Hridaya* (heart), *Basti* (urinary bladder) and *Shira* (head) are considered as most important as these are most important and prominent sites of *Prana* or vitality and leads to severe disability when traumatised.^[12] Even among these three, *Shira* is of utmost important as total 37 *Marmas* are residing there.^[13] Some of these *Marmas* are associated with special senses like vision, olfaction, taste and hearing. But here we will be concentrating on *Phana Marma* and its relation with sense of smell.

MATERIAL AND METHODS

As it is a review article, all ancient and modern texts about *Phana Marma*, olfactory system and anatomy of nose were reviewed.

Access this article online	
Quick Response Code	https://doi.org/10.47070/ijapr.v11iSuppl4.2931
	Published by Mahadev Publications (Regd.) publication licensed under a Creative Commons Attribution-NonCommercial-ShareAlike 4.0 International (CC BY-NC-SA 4.0)

DISSCUSSION

• Position of *Phana Marma*

Ayurvedic Perspective

The very first explanation about location of *Phana Marma* is from *Sushrut Samhita* as "*Ghranamargam Ubhayata Strotomarga Pratibaddhe Abhyantaratah Phane*".^[13] It means *Phana Marma* is located somewhere inside the nostrils and associated with *Strotas* present inside the nose. *Dalhana* has further specified its position by mentioning its bilateral presence.^[14] Further precision of position is added by *Acharya Vagbhata* by mentioning relation of *Marma* with *Shrotrapatha*.^[15]

The name of *Marma, Phana* is a Sanskrita word for hood of snake, defining its resemblance with hood of snake, narrowing down posteriorly from broader anterior part.^[16]

Modern Perspective

From description from *Sushruta Samhita*, it is crystal clear that *Phana Marma* is situated inside both nostrils and as per *Arundatta tika* it resembles with hood of snake.^[16] This *Phana* like part is present in the nose near posterior nasal aperture measuring 2.5cm vertically and 1.3cm transversally.^[17] which is in continuation with nasopharynx with maximum width of 3.5cm narrowing down upto 1.5cm at pharyngo-oesophageal junction.^[18] So the *Phana Marma* lies inside nasal cavity and its boundaries may extend upto Pharyngo-oesophageal junction.

But as described by *Acharya Vagbhata* this *Marma* is associated with *Shrotrapatha*.^[15] Such connection can be visualised on lateral wall of nasopharynx, described by Grey's as: "On either side each receives the opening of pharyngo-tympanic tube (also termed as Auditory or Eustachian tube), situated 10-12mm behind and little below the level of inferior nasal turbinate's posterior end"^[19]. [Figure 2] So this reference narrows the position of *Phana Marma* upto nasal cavity and nasopharynx.

Phana Marma is described as *Sira Marma* having rich vasculature, *Vaikalyakara* leading to disability on trauma and have dimension $\frac{1}{2}$ *Angula*^[14] means approximately $\frac{3}{8}$ inch or 0.93 cm.^[21] And trauma to this area leads to *Gandha-adnyana*^[13] that is loss of olfaction or complete loss of sense of smell.

Epithelium covering postero-dorsal part of nasal cavity differs from rest as it has olfactory receptor cell. This olfactory epithelium covers the area of about 10cm² stretching over posterior-upper part of lateral nasal wall, back of superior concha, sphenoidal recess, upper part of perpendicular plate of ethmoid bone & roof of nose.^[22] So the position of *Phana Marma* is now confined to upper $\frac{1}{3}$ rd of nasal cavity.

For further precision, we have to reconsider definition of *Marma* where these are described as articulation of *Mansa* (muscular part), *Sira* (vasculature), *Snayu* (tendons), *Asthi* (bone) and *Sandhi* (joints).^[3] But still every *Marma* shows predominance of one of these elements. *Phana Marma* is described as a *Sira Marma*.^[14] Main feature of such *Siras* is *Saran* or passage from one area of body to other. In brief, these are associated with transport of impulses.^[23] Such fine meshwork of unmyelinated sensory fasciculi are present over olfactory epithelium which transverses foramina of cribriform plate and unite with olfactory bulb.^[17] So this sensory plexus can be correlated with *Sirajal* present over that region.

Hence from above discussion, *Phana Marma* can be considered as the part of upper $\frac{1}{3}$ rd of nasal cavity along with its roof and olfactory bulbs resting on it. In short *Phana Marma* comprises of olfactory receptors in nasal cavity, joining together to form olfactory bulb, While the respiratory epithelium present in lower $\frac{2}{3}$ rd can be considered as periphery of *Marma*. [Figure 3] So as to have a deep knowledge of *Phana Marma* one should have good knowledge of histology of olfactory epithelium and process of olfaction.

Features of Olfactory Epithelium

Yellowish brown olfactory epithelium present over upper $\frac{1}{3}$ rd of nasal cavity comprises of pseudostratified squamous epithelium and lamina propria containing olfactory fascicles and glands. [Figure 4] The features of these cells are associated with normal process of olfaction.

Regeneration of Olfactory Receptor Cells

Olfactory receptor cells get degenerated and shed from epithelium after completing life-span of 2-3 weeks. These cells are phagocytised by supporting cells. As the degeneration process further, to maintain balance of cell count, basal epithelium undergoes mitosis and differentiation. These newly formed cells migrate apically and replace worn out olfactory receptors.^[22]

Obviously, the rate of mitosis depends on rate of degeneration. Conditions like local damage or inflammation, increasing rate of degeneration also leads to increased rate of regeneration. But in some cases this balance gets disturbed and respiratory epithelium replaces olfactory one.

• Physiology of Olfaction

Olfaction or sense of smell is depending on odorants, so it is essential to have brief knowledge of odorants.

Concept of *Gandha*

Gandha is a sense which is interpreted by *Ghran indriya* that is the nose. Broadly classified into two groups – *Surabhi* that is pleasant and *Asurabhi* that is

unpleasant and are accomplished by *Prithvi Mahabhuta*.^[23]

Sense of Smell

Sensation of smell is produced because of chemical substances that are odorants, which are divided into 1000 types like camphoraceous, musky, floral etc. But these odorants are broadly divided into 2 groups: Pleasant and Unpleasant.^[24]

Ayurvedokta Gandha Grahana Prakriya (Process of Olfaction)

According to Ayurveda, *Indriya Buddhi* or special senses are generated by *Sannikarsha* (contact) between *Indriya* (sense organ), *Mana* (mind) and *Aatma* (soul).^[25] When *Indriya-artha* that is subject of inference of organ here odorant molecules comes in contact with *Ghranendriya* in *Nasa*, leads to generation of *Ghranabuddhi* or sense of smell at the level of nose. This is then transferred and interpreted by mind residing in head. *Prana Vayu*^[26] with its *Chala Guna*^[27] is most important mediator involved in all these process. So any disruption in this cascade is always associated with vitiation of *Prana Vayu* hampering the sense of smell and may also affect other senses.

Pathway of Olfaction

The first event in perception of smell takes place at olfactory epithelium of nose. While actual perception takes place at thalamus and hypothalamus, this is known as olfactory pathway.^[24,28] [Figure 5]

• *Phana Marmagata*

Any trauma to *Phana Marma* leads to *Gandha-adnyana*^[13] that is loss of sensation of smell. Not only mechanical trauma, but iatrogenic trauma during *Chedana* (excision), *Bhedana* (incision and drainage) and chemical injury caused due to *Kshara* or *Agni Karma* also leads to similar symptoms.^[29] Any of the such a trauma injures *Nasagata Siras* especially *Vatavaha Siras* which are associated with normal motor functions and special senses like vision or smell.^[30]

• Olfactory Dysfunction

Any disruption in sense of smell is considered as olfactory dysfunction. Such olfactory dysfunction includes various condition ranging from hyposmia (reduced sensation of smell), parosmia (distorted quality of smell) or anosmia (Complete absence of sense of smell)^[31] Inability to odorant molecules to reach the olfactory receptor cells or damage to these odorant perceiving receptor cells are local causes for olfactory dysfunction.

• Trauma to Olfactory Epithelium

Olfactory epithelial lesion is either caused by direct epithelial damage caused by exposure to toxins

or due to selective neuronal degeneration after axonal damage.^[32] Axonal damage is considered as more grave than previous one, as regenerated neurons in such a condition are immature and can't make complete transition to olfactory receptor cells. In such a case, even if regeneration occurs, there are significant errors in re-innervation of olfactory bulb, leading to disturbed sense of smell. While in prior condition, any spared part of olfactory epithelium regenerates leading to its recovery. But this procedure is almost incomplete and some part of olfactory epithelium again leading to disturbed sense of smell.

Even the chemical trauma caused by toxins like cadmium leads to harmful effects on neurons including calcium channel blockade and apoptosis, which leads to olfactory dysfunction. Furthermore, these toxins may transverse to central nervous system through olfactory nerve leading to serious consequences.^[33] Even after Upper Respiratory Tract Infection, Post-Viral Olfactory Disorders may persist as a consequence. Animal studies proved that viruses are still present in neurons even for 12 days post-infection. Even if complete mechanism is unknown, such infections leads to olfactory dysfunction^[34] due to impaired regeneration of receptor and neurons^[35] [Figure 6]

• Trauma to Respiratory Epithelium

As described earlier, as olfactory epithelium can be considered as *Phana Marma* hence obviously respiratory epithelium becomes its periphery. Any lesion to respiratory epithelium like inflammation or surgical injury also interferes with integrity of olfactory epithelium. Sometimes oedema of nasal respiratory epithelium causes failure of odorant molecules to reach the olfactory epithelium, leading to temporary anosmia.^[31]

Along with acute oedematous condition, chronic inflammatory disorders like rhino-sinusitis leads to goblet cell hyperplasia and squamous cell metaplasia which in turn causes erosion of olfactory neurons and supporting cells^[36] leading to olfactory dysfunction. But this condition can be reversed upto some extent by decreasing mucosal oedema using corticosteroids.^[31]

Operations performed for treatment of chronic nasal inflammatory disorders also affects morphology of nasal cavity. Some of these procedures may lead to permanent damage to olfactory epithelium.^[37] As these diseases or lesions are associated with periphery of *Phana Marma*, they are difficult to treat generally leading to hyposmia or parosmia.^[38]

Figure 1: Classification of *Marmas* As per *Aghatajanya Lakshane* [6,7] (Symptoms after trauma)

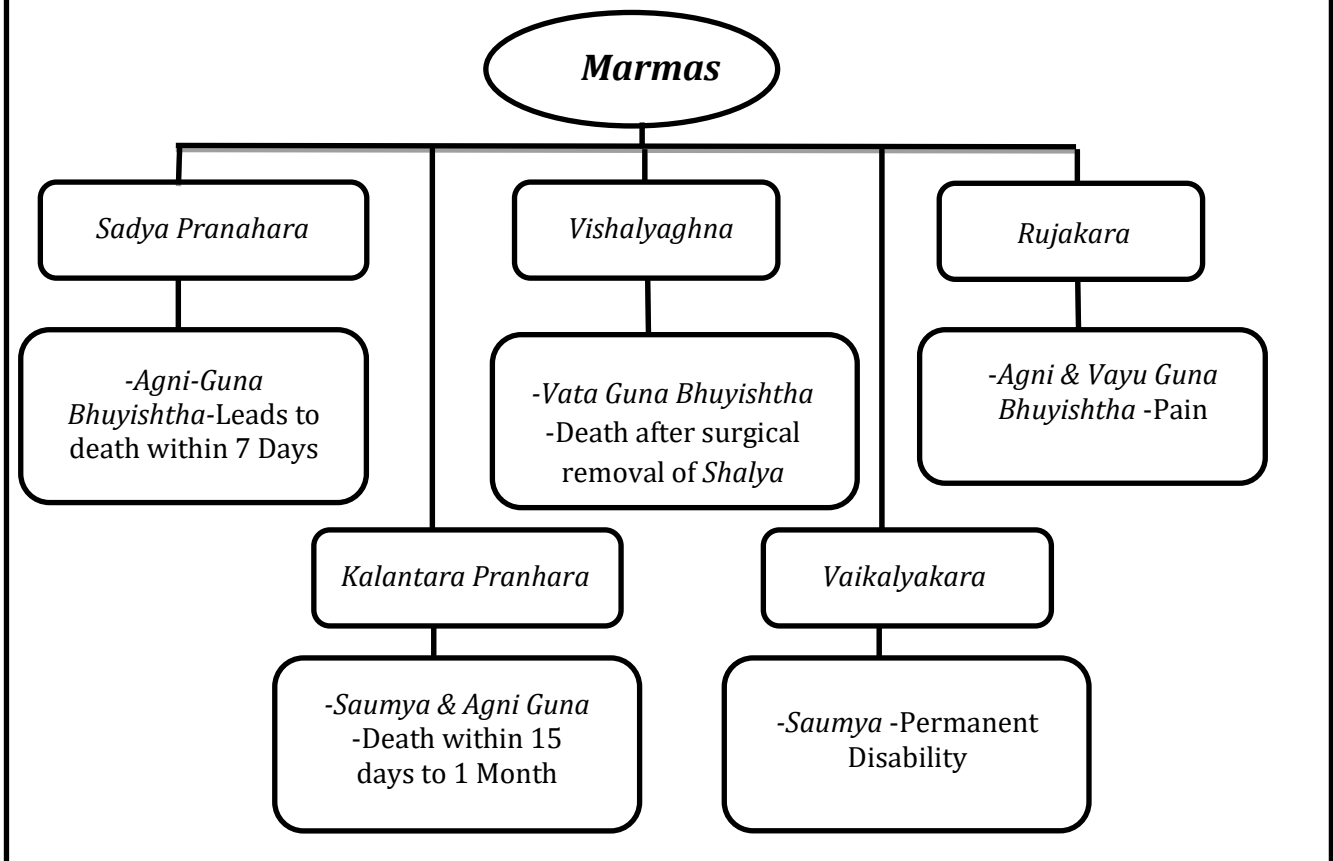


Figure 2: Nasal Cavity & Nasopharynx Transverse Section [20]

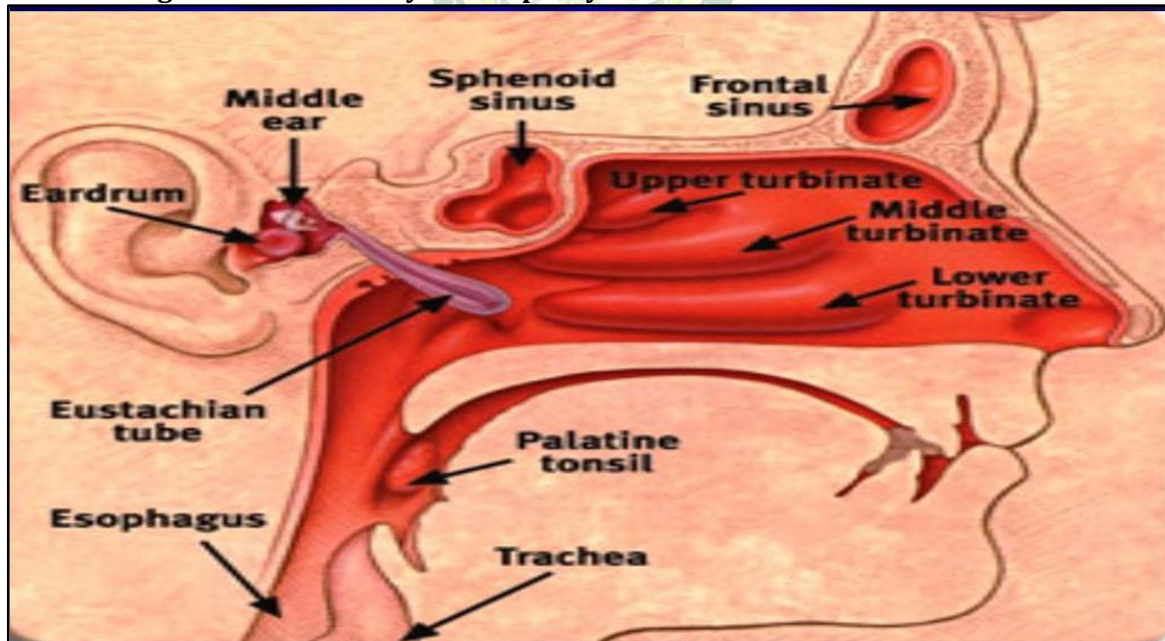
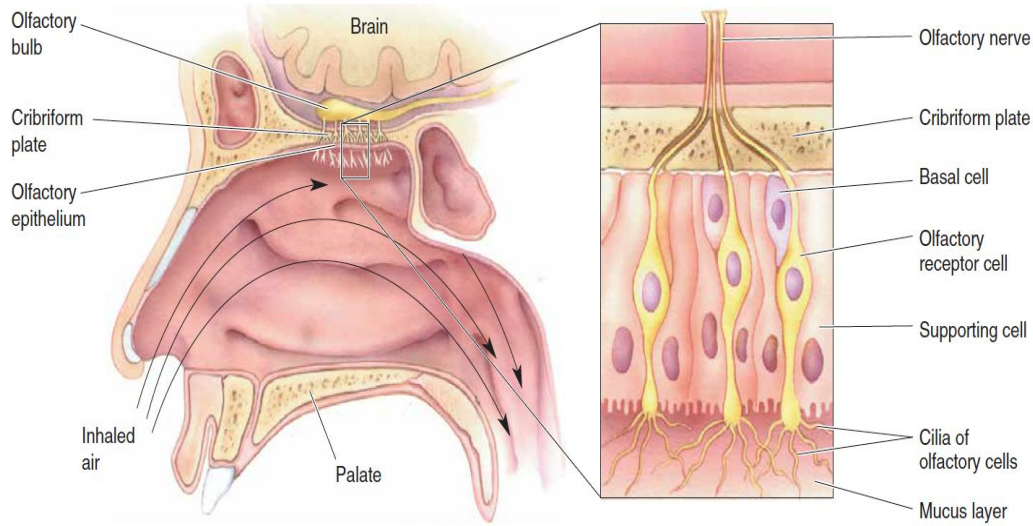


Figure 3: Phana Marma : Olfactory Epithelium [24]



▲ FIGURE 8.9

The location and structure of the olfactory epithelium. The olfactory epithelium consists of a layer of olfactory receptor cells, supporting cells, and basal cells. Odorants dissolve in the mucus layer and contact the cilia of the olfactory cells. Axons of the olfactory cells penetrate the bony cribriform plate on their way to the CNS.

Figure 4: Histology of Olfactory Epithelium[22]

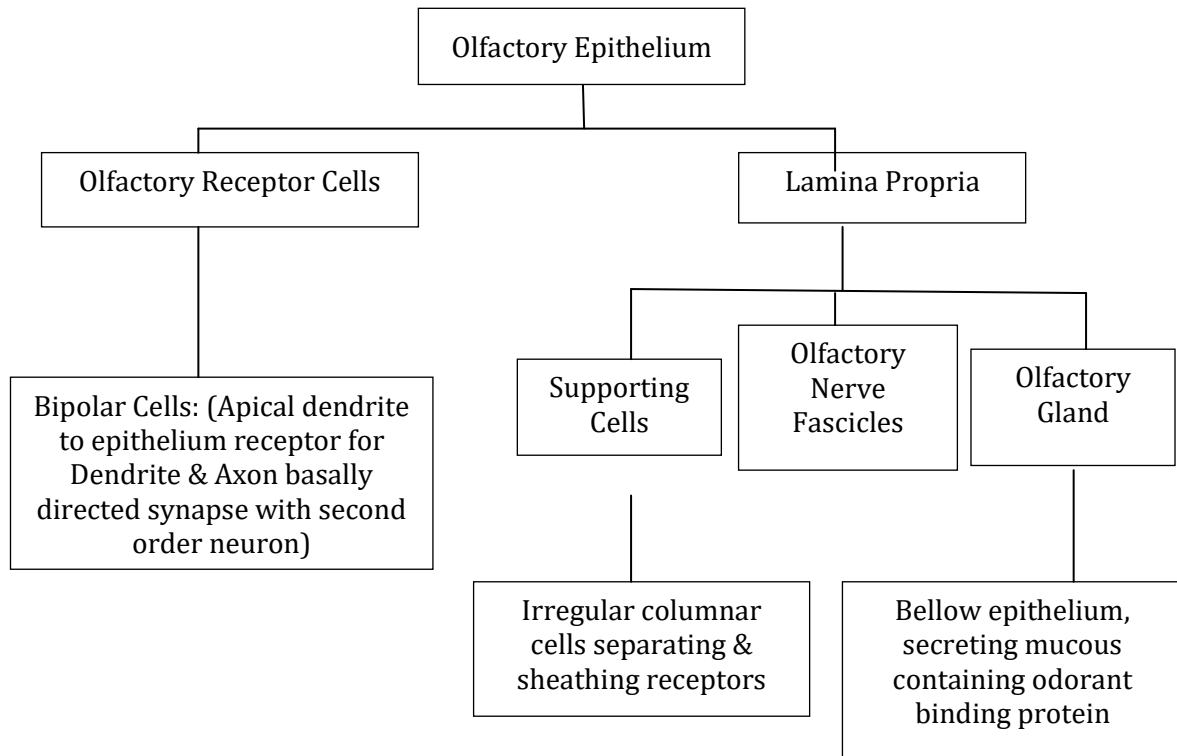


Figure 5 : Olfactory Pathway

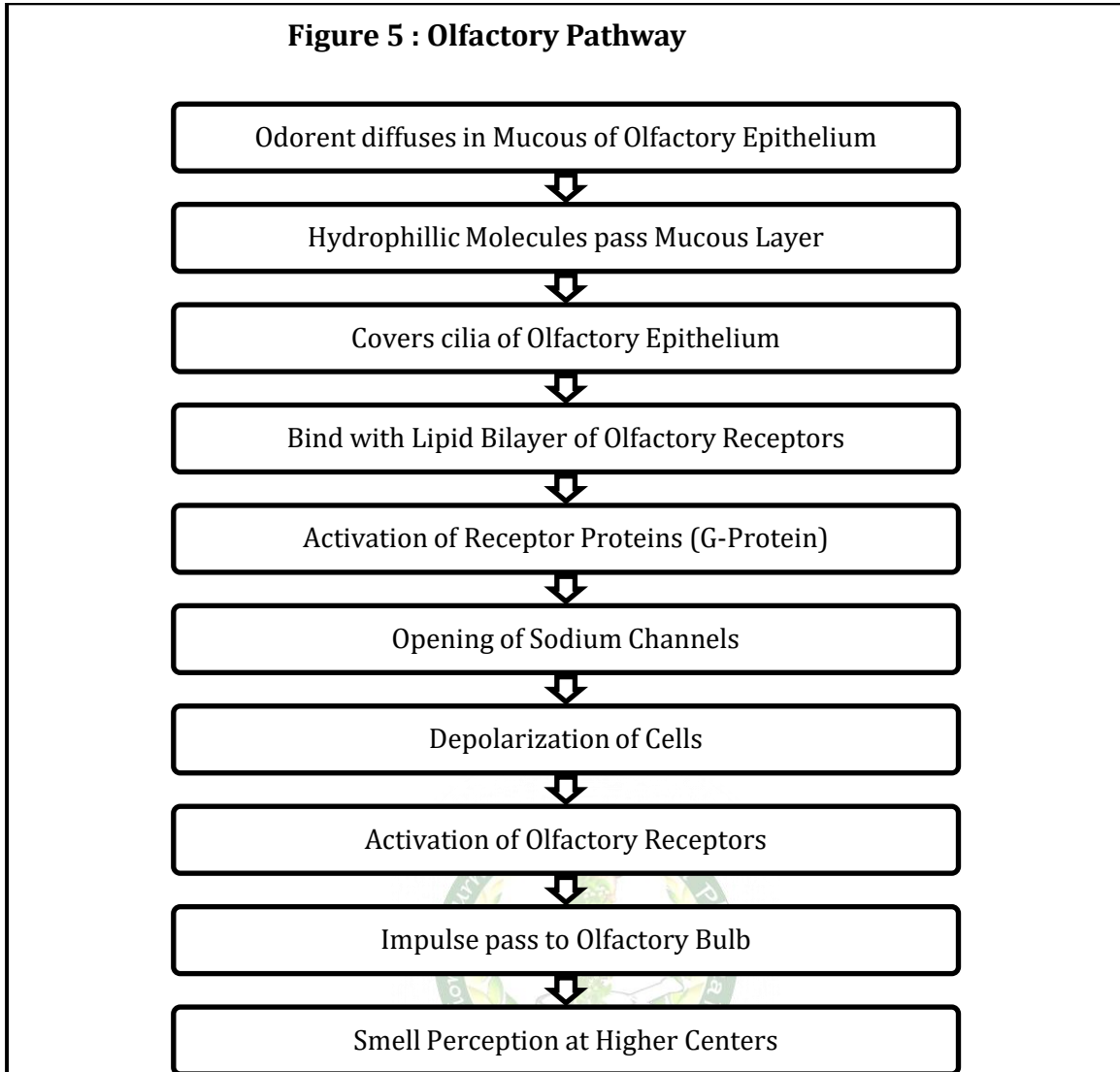


Figure 6: Olfactory Epithelium Regeneration after chemical injury

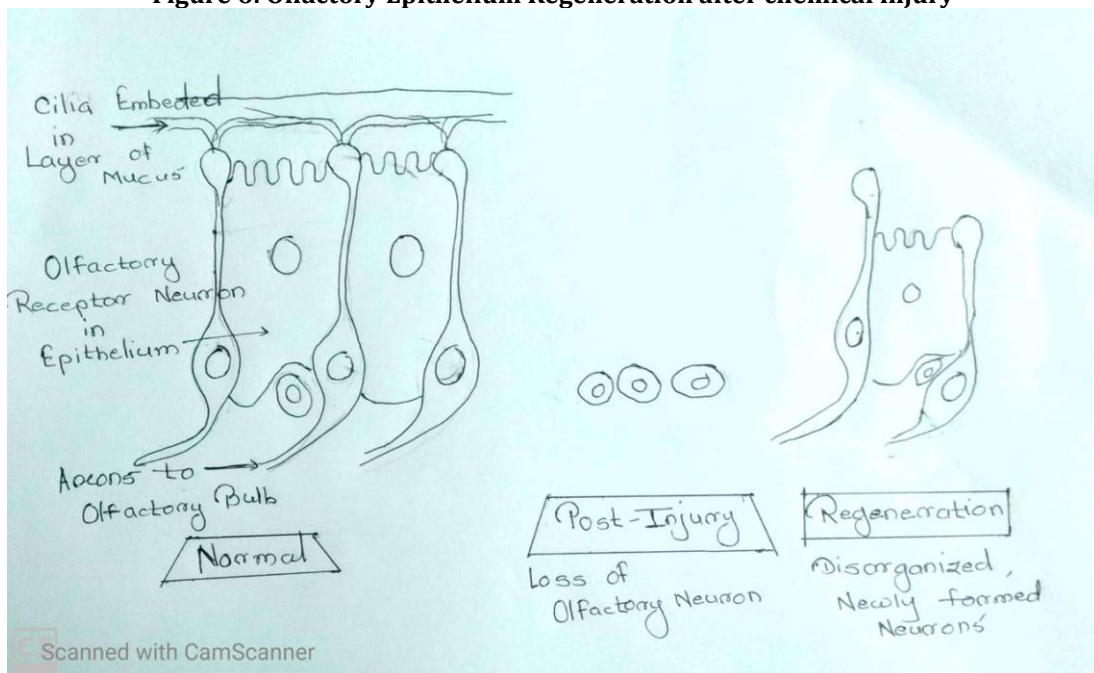


Figure 7 : Location of Phana Marma^[39]

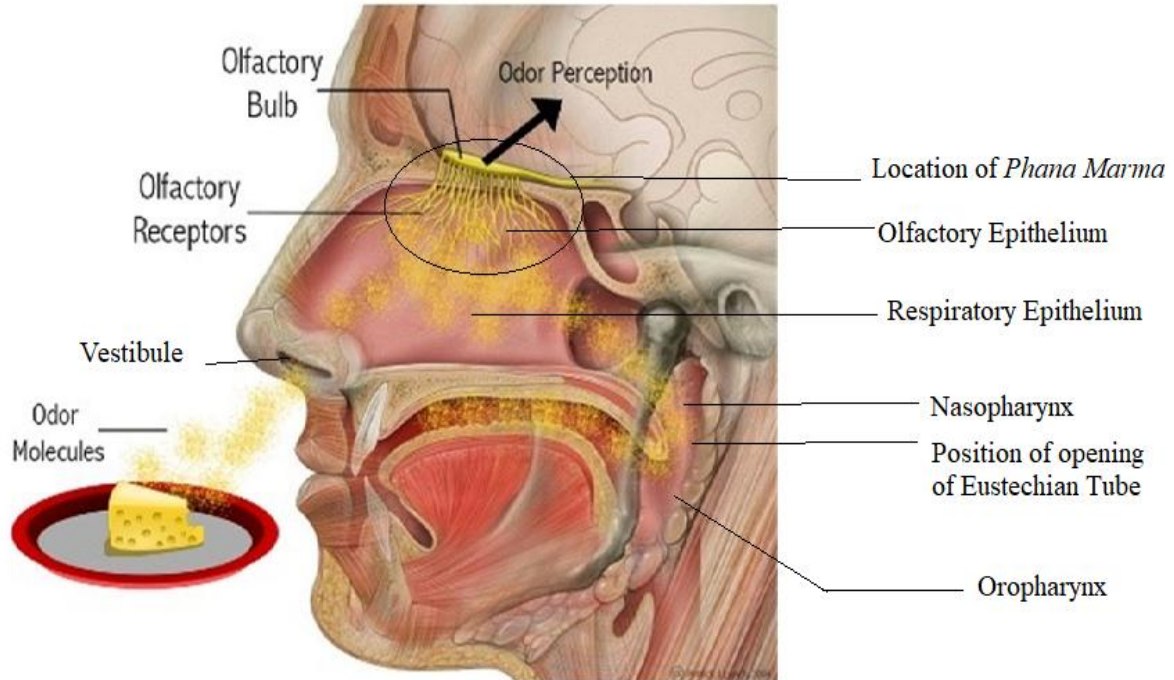


Table 1: Comparison between Phana Marma and Olfactory Epithelium & Olfactory Neurons

	Phana Marma	Olfactory Epithelium & Neurons
Position	<i>Ubhayata Nasa Abhyantaratah Shrotrapathanugata</i>	Upper 1/3 rd region of nasal cavity adjacent to roof of nose (Olfactory Receptors & Neurons)
Function	<i>Gandha Dyana</i>	Olfaction or Sense of Smell
Lesion	<i>Gandha Adnyana</i>	Loss of Sensation of Smell or Disability
Lesion to Periphery	<i>Alpa Pramanat Gandha Adnyana</i>	Temporary loss of Olfaction or Impaired Sense of Smell
Regeneration Capacity	<i>Alpa</i>	Limited upto Certain Extent

CONCLUSION

Finally to conclude, from all above discussion précised position of *Phana Marma* can be considered as olfactory epithelium [Table 1] [Figure 7] situated in upper 1/3rd region of nasal cavity and olfactory neurons crossing roof of nose and connecting olfactory receptors to olfactory bulb. Lesion of any of these structures or any lesion affecting integrity of nasal mucosa, is associated with olfactory dysfunction either temporary or permanent which is generally grave to treat.

REFERENCES

1. Editor Yadavaji Trikamaji, Charak Samhita Sutrasthan Adhyaya 30 Shloka No.26; Page No. 187. Charak Samhita with Chakrapani Datta Virachit Ayurveda Dipika Tika, Published by Chaukhamba Surbharati Prakashana, Reprint 2017.
2. Editor Yadavaji Trikamaji, Charak Samhita Siddhi-Sthan Adhyaya 9 Shloka No.10; Page No. 718. Charak Samhita with Chakrapani Datta Virachit Ayurveda Dipika Tika, Published by Chaukhamba Surbharati Prakashana, Reprint 2017.
3. Publisher Yadavaji Trikamaji, Sushrut Samhita Sharirasthan, Adhyaya 06, Shloka 15. Page 371. Sushrut Samhita with Dhalankrita Nibhanda sangraha tika. Publication: Chaukhamba Krishnadas Akadami, Varanasi. Reprint 2008.
4. Publisher Yadavaji Trikamaji, Sushrut Samhita Sharirasthan, Adhyaya 06, Shloka 35. Page 375. Sushrut Samhita with Dhalankrita Nibhanda sangraha tika. Publication: Chaukhamba Krishnadas Akadami, Varanasi. Reprint 2008.
5. Publisher Yadavaji Trikamaji, Sushrut Samhita Sharirasthan, Adhyaya 06, Shloka 3. Page 369. Sushrut Samhita with Dhalankrita Nibhanda sangraha tika. Publication: Chaukhamba Krishnadas Akadami, Varanasi. Reprint 2008.
6. Publisher Yadavaji Trikamaji, Sushrut Samhita Sharirasthan, Adhyaya 06, Shloka 16. Page 371. Sushrut Samhita with Dhalankrita Nibhanda sangraha tika. Publication: Chaukhamba Krishnadas Akadami, Varanasi. Reprint 2008.

7. Publisher Yadavaji Trikamaji, Sushrut Samhita Sharirsthan, Adhyaya 06, Shloka 23. Page 372. Sushrut Samhita with Dhalankrita Nibhanda sangraha tika. Publication: Chaukhamba Krishnadas Akadami, Varanasi. Reprint 2008.
8. Publisher Yadavaji Trikamaji, Sushrut Samhita Sharirsthan, Adhyaya 06, Shloka 19. Page 371. Sushrut Samhita with Dhalankrita Nibhanda sangraha tika. Publication: Chaukhamba Krishnadas Akadami, Varanasi. Reprint 2008.
9. Publisher Yadavaji Trikamaji Sushrut Samhita Sharirsthan, Adhyaya 07, Shloka 3. Page 376. Sushrut Samhita with Dhalankrita Nibhanda sangraha tika. Publication: Chaukhamba Krishnadas Akadami, Varanasi. Reprint 2008.
10. Publisher Yadavaji Trikamaji, Sushrut Samhita Sharirsthan, Adhyaya 06, Shloka 43. Page 376. Sushrut Samhita with Dhalankrita Nibhanda sangraha tika. Publication: Chaukhamba Krishnadas Akadami, Varanasi. Reprint 2008.
11. Parikshakarta Hari Paradkar. Ashtang hrdayam Sharir sthan Adhyaya 4, Shloka no. 68; page 416. Astangahridayam Shrimat Arrunadatta Virachita Sarvanga Sundar Vyakhyaya Hemadripranita Ayurveda Rasayana Tikaya Samullasita, Publication: Chaukhamba Surbharati Prakashan. Reprint 2017.
12. Editor Yadavaji Trikamaji. Charak Samhita Siddhi-Sthan Adhyaya 9 Shloka No.3; Page No. 716. Charak Samhita with Chakrapani Datta Virachit Ayurveda Dipika Tika, Published by Chaukhamba Surbharati Prakashana, Reprint 2017.
13. Publisher Yadavaji Trikamaji. Sushrut Samhita Sharirsthan, Adhyaya 06, Shloka 27. Page 374. Sushrut Samhita with Dhalankrita Nibhanda sangraha tika. Publication: Chaukhamba Krishnadas Akadami, Varanasi. Reprint 2008.
14. Publisher Yadavaji Trikamaji. Sushrut Samhita Sharirsthan, Adhyaya 06, Shloka 27 Dalhana Tika. Page 374. Sushrut Samhita with Dhalankrita Nibhanda sangraha tika. Publication: Chaukhamba Krishnadas Akadami, Varanasi. Reprint 2008.
15. Parikshakarta Hari Paradkara. Astangahrdayam Sharir sthan Adhyaya 4, Shloka no. 30; page 412. Astangahridayam Shrimat Arrunadatta Virachita Sarvanga Sundar Vyakhyaya Hemadripranita Ayurveda Rasayana Tikaya Samullasita, Publication: Chaukhamba Surbharati Prakashan. Reprint 2017.
16. Parikshakarta Hari Paradkar. Astangahrdayam Sharir sthan Adhyaya 4, Shloka no. 30 Sarvangsundar Tika; page 412. Astangahridayam Shrimat Arrunadatta Virachita SarvangaSundar Vyakhyaya Hemadripranita Ayurveda Rasayana Tikaya Samullasita Publication: Chaukhamba Surbharati Prakashan. Reprint 2017.
17. Editorial Board: P. Williams, L. Bannister, M. Berry, P. Collins, M. Dyson, J. Dussek, M. Ferguson. Gray's Anatomy, The Anatomical Basis of Medicine & Surgery. Respiratory System: Nose, Nasal Cavity & Paranasal Sinuses, Page 1632. 38th Edition Year 1995, Publication: ELBS with Churchill Livingstone.
18. Writer A.K.Datta. A.K.Datta Essential of Human Anatomy, Part 2, Head & Neck. Pharynx, Palatine Tonsils & Auditory Tube; Page 289, 5th Edition. Publication: Current Book Internationals.
19. Editorial Board: P. Williams, L. Bannister, M. Berry, P. Collins, M. Dyson, J. Dussek, M. Ferguson Gray's Anatomy, The Anatomical Basis of Medicine & Surgery. Alimentary System – Pharynx, Page 1726.; 38th Edition Year 1995, Publication: ELBS with Churchill Livingstone.
20. ENT - Ears, Nose, Throat – Pinterest, <https://in.pinterest.com/entclinicgurgaon/ent-specialist>
21. Commentator Dr. Brahmanand Tripathi. Sarangadhara Samhita Purva Khanda Adhyaya 1: Paribhasha Prakarana Page 15. Sarngadhara-Samhita Annotated with Dipika Hindi Commentary., Chaukhamba Surbharati Prakashana, Reprint 2016.
22. Editorial Board: P. Williams, L. Bannister, M. Berry, P. Collins, M. Dyson, J. Dussek, M. Ferguson Gray's Anatomy, The Anatomical Basis of Medicine & Surgery, Nervous System: Olfactory Nerve, Page 1315. 38th Edition Year 1995, Publication: ELBS with Churchill Livingstone.
23. Writer: Dattatraya VasudevJog Tarkasangraha Guna Grantha 20, 21; Page 32. Mahamahopadhyaya Shri Annabhata Virachita Tarkasangraha, 5th Edition, Publisher: M.D.Jog, Year2010
24. Written and Published by Guyton and Halls. Guyton and Hall - Textbook of Medical Physiology: Chapter 53: Nervous System: Chemical Senses: Taste & Smell, Page 648-652.
25. Guyton and Hall Textbook of Medical Physiology, 12th Edition Reprint 2011, Publication: Saunders An imprint of Elsevier. Guyton
26. Editor Yadavaji Trikamaji. Charak Samhita Sutra-Sthan Adhyaya 8 Shloka No.12 Chakrapani Datta Tika; Page No. 56 & 57. Charak Samhita with ChakrapaniDatta Virachit Ayurveda Dipika Tika, Published by Chaukhamba Surbharati Prakashana, Reprint 2017.
27. Parikshakarta Hari Paradkar. Astangahrdayam Sutra sthan Adhyaya 12, Shloka no. 4 & 5, page 193. Astangahridayam Shrimat Arrunadatta Virachita Sarvanga Sundar Vyakhyaya Hemadripranita Ayurveda Rasayana Tikaya Samullasita, Publication: Chaukhamba Surbharati Prakashan. Reprint 2017.
28. Parikshakarta Hari Paradkar. Astangahrdayam Sutra sthan Adhyaya 1, Shloka no. 11, page 09.

- Astangahridayam Shrimat Arrunadatta Virachita Sarvanga Sundar Vyakhyaya Hemadripranita Ayurveda Rasayana Tikaya Samullasita, Publication: Chaukhamba Surbharati Prakashan. Reprint 2017.
29. Editor S. Musheer Hussain, Logan Turner's Diseases of the Nose, Throat and Ear Head and Neck Surgery. Section 1: Nose, Chapter 1: Anatomy & Physiology of Nose & Paranasal Sinuses, Page 9-12, 11th Edition, Printed 2016, Publication: CRC Press, Taylor & Francis Group Logan
30. Publisher Yadavaji Trikamaji, Sushrut Samhita Sharirsthan, Adhyaya 06, Shloka 40. Page 376. Sushrut Samhita with Dhalankrita Nibhanda sangraha tika. Publication: Chaukhamba Krishnadas Akadami, Varanasi. Reprint 2008.
31. Publisher Yadavaji Trikamaji, Sushrut Samhita Sharirsthan, Adhyaya 07, Shloka 8. Page 377. Sushrut Samhita with Dhalankrita Nibhanda sangraha tika. Publication: Chaukhamba Krishnadas Akadami, Varanasi. Reprint 2008.
32. Editor S.Musheer Hussain, Logan Turner's Diseases of the Nose, Throat and Ear Head and Neck Surgery. Section 1: Nose, Chapter 13: Smell & Anosmia, Page 111-118, 11th Edition, Printed 2016, Publication: CRC Press, Taylor & Francis Group Logan
33. J.E.Schwob; Neural Regeneration & The Peripheral Olfactory System. The Anatomical Record (New Anat.) 269:33-49, 2002
34. LA Czarnedci et. al., In Vivo Visualization of Olfactory Pathophysiology Induced by Intranasal Cadmium Instillation in Mice.
35. Czarnecki LA, Moberly AH, Rubinstein T, Turkel DJ, Pottackal J, McGann JP. In vivo visualization of olfactory pathophysiology induced by intranasal cadmium instillation in mice. Neurotoxicology. 2011 Aug;32(4):441-9
36. Tian J, Pinto JM, Cui X, Zhang H, Li L, Liu Y, Wu C, Wei Y. Sendai Virus Induces Persistent Olfactory Dysfunction in a Murine Model of PVOD via Effects on Apoptosis, Cell Proliferation, and Response to Odorants. PLoS One. 2016 Jul 18;11(7):e0159033. doi: 10.1371/journal.pone.0159033. PMID: 27428110; PMCID: PMC4948916.
37. Ibid
38. Tian J, Pinto JM, Cui X, Zhang H, Li L, et al. (2016) Sendai Virus Induces Persistent Olfactory Dysfunction in a Murine Model of PVOD via Effects on Apoptosis, Cell Proliferation, and Response to Odorants. PLOS ONE 11(7): e0159033. <https://doi.org/10.1371/journal.pone.0159033>
39. Olfactory Epithelium Cells, Clinical Disorders & Insight From An Adult Stem Cell Niche. Laryngoscope: Investigative Laryngology, Volume 3, Issue 1, 2018, Page 39-45.

Cite this article as:

Sukhada Kulkarni. Concept of Phana Marma in Ayurveda and its Relation with Olfaction. International Journal of Ayurveda and Pharma Research. 2023;11(Suppl 4):11-19.

<https://doi.org/10.47070/ijapr.v11iSuppl4.2931>

Source of support: Nil, Conflict of interest: None Declared

***Address for correspondence**

Dr. Sukhada Kulkarni

Assistant Professor,
PZET's College of Ayurveda &
Research Center, Akurdi, Pune.

Email:

dr.sukhadak@gmail.com

Disclaimer: IJAPR is solely owned by Mahadev Publications - dedicated to publish quality research, while every effort has been taken to verify the accuracy of the content published in our Journal. IJAPR cannot accept any responsibility or liability for the articles content which are published. The views expressed in articles by our contributing authors are not necessarily those of IJAPR editor or editorial board members.