



## Case Study

### AN AYURVEDIC APPROACH IN THE MANAGEMENT OF NEUROCYSTICERCOSIS: A CASE STUDY

Amit Nakanekar<sup>1\*</sup>, Suraj Rathod<sup>2</sup>, Rajni Gurmule<sup>2</sup>, Ajit Devikar<sup>2</sup>, J.D.Gulhane<sup>3</sup>

<sup>1</sup>Assistant professor, <sup>2</sup>PG Student, <sup>3</sup>Associate Professor, Government Ayurved College (GAC) Nagpur, India.

Received on: 20/09/2015

Revised on: 06/10/2015

Accepted on: 16/10/2015

#### ABSTRACT

Neurocysticercosis is form of cysticercosis. It is a infection of the brain by the larval form of the pork tapeworm taenia solium. In 80% cases symptoms are seizures, visual disturbance, nausea, abdominal cramps, and diarrhoea. Among the rare incidences some abnormal symptoms occur are dysarthria, extra ocular movement palsy, hemiplegia, movement disorder, gait disturbance.

A 49 year old male patient came to OPD of GAC Nagpur with complaints of weakness in left side of upper and lower limb, slurred speech, focal convulsion of left hand, difficulty in walking since 10 days and having H/O seizures 30 year ago. Patient was diagnosed as a case of Neurocysticercosis through CT brain, CSF, and other haematological investigations. Patient was admitted and treated with Ayurvedic principle of *Krimi* and *Vatavyadhi* management. Patient showed complete recovery in clinical assessments in terms of speech, gait weakness.

**KEYWORDS:** Neurocysticercosis, *Krimi*, *KrimiKuthar Ras*, *Tantu Pashan Vati*, *Vidangarisht*.

#### INTRODUCTION

Neurocysticercosis is a the commonest parasitic disease of Human Nervous system, Immunological assays detect positivity for human in cysticercosis in 8-12 % of people in some endemic region, cysticercosis is disease caused by tapeworm taenia solium distributed worldwide where sanitation is poor<sup>1</sup>. The main clinical manifestation of Neurocysticercosis are seizures, headache and focal neurological deficits, it can have sequela like epilepsy, hydrocephalus, dementia<sup>1</sup>, the introduction of praziquantel and albendazole as a specific antiparasitic agents were enthusiastically adopted by many segments of medical community<sup>2,3</sup>.

Ayurveda has mentioned 20 types of *Krimi* (worms). *Apakarshan* (Throw worm from the body), *Prakruti Vighat* (Antidote of *Krimi*) and *Nidanparivarjan* (avoidance of causative factors) are the 3 basic principles maintained in *Ayurveda* for complete treatment of *Krimi*.<sup>4</sup>

#### Case Report

A 49 year old male patient came to OPD (OPD NO. CR-29761 ON 19/6/14) with complaints of weakness in left side of upper and lower limb, slurred speech, focal convulsion of left hand, difficulty in walking since 10 days.

He was brought by relative to Govt. Ayurvedic Hospital, Nagpur. Patient was admitted (IPD NO. 2891 ON 19/6/14) treated with Ayurvedic treatment. He did not have any history of Diabetes, Hypertension,

Asthma, Tuberculosis, or any major surgical procedure. He had history of occasional consumption of alcohol. No history of any specific medication or drug abuse.

#### Past History

Patient was apparently alright 10 day ago. Then He had developed gradual weakness in left side of upper and lower limb, slurred speech, focal convulsion of left hand, difficulty in walking. For these complaints he took treatment from private practitioner but he did not get relief and hence came to Government Ayurvedic College (GAC) Nagpur.

Patient had H/O convulsion 20 year ago.

#### Examination on Admission

##### General Examination

The Patient was afebrile and his pulse was 110/min, Blood pressure 130/80. He appeared pale and he had moderate weight (59 kg)

##### Physical Examination

There was diffuse weakness of left side of upper and lower limb, focal convulsion of left hand, patient was unable to walk and unable to sit without support.

##### Systemic Examination

In the systemic examination findings of Respiratory and Cardiovascular System were within the normal limits. Abdomen was soft, non-tender, and bowel sounds were present.

### Neurological Examination

Patient was conscious and well oriented and pupillary reaction to light was normal.

#### DTR :

Reflexes	Ankle	Knee	Bicep	Triceps	Plantar
Right	++	++	++	++	++
Left	+++	+++	+++	+++	+++

#### MPG:

	Arms	Legs
Right	5/5	5/5
Left	2/5	2/5

**Gait :** Patient unable to walk, sit and stand

#### Ashtavidha Parikasha

- 1.Nadi-98/min; 2.Mala-Samyak; 3.Mutra- Samyak;
- 4.Jivha- Niram; 5.Drik- Spashta; 6.Sparsh- Samshitoshna
- 7.Shabda-Aspsth; 8.Aakriti- Madhyam

#### Vikrit Srotas Parikshan

Mamsavaha Srotasvikrti was presented as Vamhastapad daurbalya. While Majjavaha Srotas showing Vamhastapadkarmahani, focal convulsion of left hand, Sakashtashabdochharan (dysarthria).

#### Investigation

Hb% : 12.2

TLC : 9000/cumm

ESR : 22 mm/hr

DLC : P(68), L(24), E+M(8)

Urine : WNL

RBS : 120 mg/dl.

CSF : Physical, Microscopic, Biological Examination are Normal

CT Brain (19/6/2014): Calcified nodular old granulomatous lesions in right temporal, parietal and high frontal regions s/o Neurocysticercosis.

#### Ayurveda treatment

Initial 7 days patient was treated with Quantity sufficient of indirectly heated *Til Taila* was applied in *Anuloma Gati* (downward) for 15 min (*Bahya Snehan*) and *Nadisvedana* by *Nirgundi* and *Dashmula siddha kwatha* for a period of 15 minutes. Patient was treated with *KrimiKuthar Ras* 125 mg tab (2 BD) *Anupana: KoshnaJala* QS; *Tantu Pashan Vati* 2 BD *Anupana: KoshnaJala* QS; *Vidangarishth* 2 tsf BD. After 7 days Patient was given above all treatment with additional *Yogbastikram* in that decoction processed with *Krimighna Dravya* in the form of *Basti* was used and *Karanjtaila Basti* was given on alternate day. *Basti* given from date 25/06/2014 to 2/7/2014 (Graph 1) After that due to personal reason patient went to home and in those day patient advice to continue above oral medicine. Patient was again admitted on dated 27/8/2014. Patient was treated with above same treatment with 2 changes, that time we replaced *Krimi kutharras* by *Krimi mudgaras* and *Yogbastikram* by *Karmbastikram*.

Date	Basti Prakar	Bastidan Time	Bastinirhana time	Matra (Quantity)
25/6/2014	Anuvasan D1	7.35pm	10.45pm	60ml
26/6/2014	Anuvasan D2	7.30pm	10.40pm	60ml
27/6/2014	Krimighnabasti D3	9.30am	10.30am	650ml
28/6/2014	Anuvasan D4	7.30pm	10.00pm	60ml
29/6/2014	Krimighnabasti D5	9.00am	9.15am	650ml
30/6/2014	AnuvasanD6	7.40pm	9.30pm	60ml
1/7/2014	Krimighna bastiD7	9.15am	10.00am	650ml
2/7/2014	AnuvasanD8	7.25pm	9.45pm	60ml

#### Result

As Ayurvedic treatment start from date 20/6/2013 patient got very beneficially effect. On admission patient unable to walk, sit without support, difficulty in speech, weakness in left side of body. Different *Panchakarma* procedures like *Snehana*, *Svedana*, *Basti*, *Krimighna Chikitsa* had improve signs and symptoms of patient. (Table 1,2,3)

Table 1: showing comparison between Reflexes of BT and AT

BT		AT	
Deep Tendon Reflexes(DTR)of left side of body		Deep Tendon Reflexes(DTR) of left side of body	
Ankle	+++	Ankle	++
Knee	+++	Knee	++
Bicep	+++	Bicep	++
Triceps	+++	Triceps	++
Superficial Reflexes		Superficial Reflexes	
Planter	Extension of Toe	Planter	Flexor

**Table 2: showing comparison between Muscle power grades during treatment course**

M.P.G.	19/6/2014	26/6/2014	28/8/2014	10/9/2014	15/9/2014
Rt.Upper Limb	5/5	5/5	5/5	5/5	5/5
Lt.Upper Limb	2/5	2/5	3/5	4/5	5/5
Rt..lower Limb	5/5	5/5	5/5	5/5	5/5
Ltlower Limb	2/5	2/5	3/5	4/5	5/5

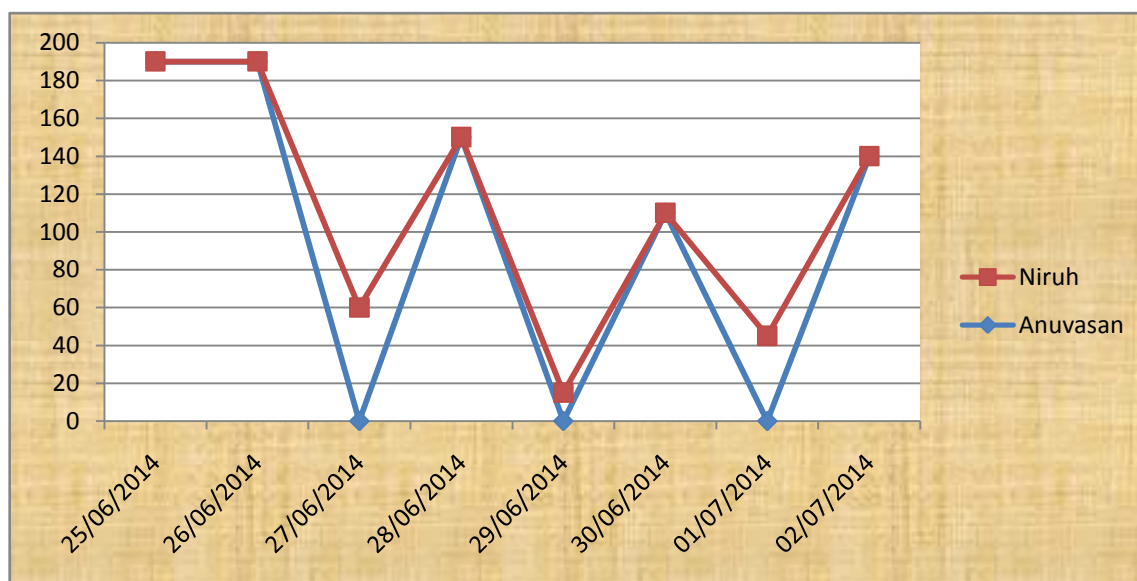
**Table 3: Table showing comparison between Gait during treatment course**

Date	Gait
19/6/2014	Patient unable to walk, sit and stand
26/6/2014	Patient can sit with full support
28/8/2014	Patient can sit with minimum support
10/9/2014	Patient walking with support and walker
15/9/2014	Patient can walk independently without support

**Graph 1 :**

X-Axis shows date of *Basti* given

Y-Axis shows *Bastipratyagamankal* in Minute



**DISCUSSION**

Above study on the neurological disorder by worm infestation has responded to the Ayurvedic management given above. The effect of the treatment is shown in above table of muscle power and reflexes showing significant result. Also there was a noticeable improvement in speech of the patient. *Krimi chikitsa* is extensively described in *Ayurveda*. Here cause of hemiplegia is *Krimi*. *Sanniprakushta* (~immediate cause of disease) and *Viprakushtahetu* (~cause of disease which shows late manifestation of disease ) are described in detail in *Ayurveda*. Tapeworm is a *Viprakushta* cause of current disease. *Krimi* removal and treatment of *Vata* are basic principles of treating the patient. *Basti* is a most important route for treatment of *Vatavyadhi*. Hence we have used *Krimignagana siddha basti*. *Krimigna herbs* are mentioned by *Charaka*<sup>(4)</sup>.

**CONCLUSION**

*Krimi chikitsa* in *Ayurveda* forms an important concept for treating various disorders. Neurocysticercosis is a disorder of tape worm infection of brain and *Ayurvedic* treatment found to be effective in this case. This single case report gives us further clue for treatment of albendazole resistant Neurocysticercosis.

**REFERENCE**

1. Artuorocarpio. Neurocysticercosis and update; the lancet infectious diseases volume 2 issue 12 december 2002 page 751-762
2. Robles C, M. Chavharria 1979 presentation de uncasoclinido de cisticercosis cerebral tratadomedicamente con un Nuevo farmaco: praziquantel. Saludpublica Mex. 21:603-618

3. Escobedo, F., P. Penagos, J. Rodriguez, and J.Sotelo. 1987. Albendazole therapy for nuerocysticercosis. Arch. Intern. Med. 147:738-741.
4. Y.G Joshi, CharakSamhita of Charaka, Vimansthan, Vyadhitrupiyaviman, chapter 7, verse 14,15. Vaidyamitra Publication, page no-559.
5. Ayurvedacharya Shreeyadunandanopadhyaya Madhav Nidan, Panchnidanlakshanam, Chapter-1.Chaukhabma Publication, page no-19.
6. Vidyadharshukla, Charaksamhita of charak, Siddhisthan, Prasutayogiya siddhi, chapter-8, verse 9-10. Chaukhabma Publication, 2009; page no-939.
7. DrBramhanand Tripathi, Astanghridayam, sutrasthan, Ayushkamiya, Chapter-1, verse 25. Chaukhabma Publication, 2009;page no-20.
8. Dr Gangasahaya Pandey, Bhavaprakash nighantu, Guduchyadivarg Chapter-3, verse 119-20, Chaukhabma Publication, 2010; page no-334.
9. Pandit Hariprapanna Sharma, Rasyogsagar volume 1, Formulation No. 321 Krimikutharoras, verse1392; Krishnadas academy publication, page no. 328.
10. Pandit Hariprapanna Sharma, Rasyogsagar volume 1, Formulation No. 326 Krimimudgar, verse1406; Krishnadas academy publication, page no. 329.

**Cite this article as:**

Amit Nakanekar, Suraj Rathod, Rajani Ghurmule, Ajit Devikar, J.D.Gulhane. An Ayurvedic Approach in the Management of Neurocysticercosis: A Case Study. International Journal of Ayurveda and Pharma Research. 2015;3(10):57-60.

**Source of support: Nil, Conflict of interest: None Declared**

**\*Address for correspondence**

**Dr. Nakanekar Amit**

Assistant Professor

Unit 3, Dept of Kayachikitsa

Government Ayurved College

Nagpur, Maharashtra, India.

Mobile: 09850233016

Email: [amitnakanekar@gmail.com](mailto:amitnakanekar@gmail.com)

